

Anesthesia Aspects of Multivisceral Transplantation: A Case Series Study

M. B. Khosravi¹, V. Naderi-boldaji¹,
F. Khalili^{1*}, M. A. Sahmeddini¹,
M. H. Eghbal¹, P. Vatankhah¹,
H. Nikoupour², A. Shamsaeefar²,
S. Ghazanfar Tehran³

¹Anesthesiology and Critical Care Research Center, Shiraz University of Medical Sciences, Shiraz, Iran
²Abu-Ali Sina Organ Transplant Center, Shiraz University of Medical Sciences, Shiraz, Iran
³Anesthesiology and Critical Care Research Center, Alzahra Hospital, Guilan University of Medical Sciences, Rasht, Iran

ABSTRACT

Background: Multi-visceral transplantation (MvTx) usually refers to the transplantation of more than three intra-abdominal organs. A successful MvTx requires strong multidisciplinary teamwork of transplant surgeons, anesthesiologists, and intensivists.

Case presentation: We present five cases of MvTx with a history of short bowel syndrome admitted to the Abu-Ali Sina Hospital, Shiraz, Iran from May 2019 to January 2020 and describe anesthetic considerations in MvTx. Subjects were identified (4F/1M) with a mean age of 43 years old (range 35–51). The most frequent cause of intestinal failure was portal vein thrombosis, followed by bowel gangrene and short bowel syndrome. The mean \pm SD duration of the operation was 360 ± 60 min. The bleeding volume was approximately 2600 ± 1474 cc, and 4 ± 1 bags of packed red blood cells were transfused. Sepsis was the main cause of death in our series.

Conclusion: Careful preoperative planning, vigilant intraoperative anesthetic management, and prevention of postoperative infection are imperative to achieve the best outcomes.

KEYWORDS: Multi-visceral transplantation; Anesthesia, Short bowel syndrome; Portal vein thrombosis

INTRODUCTION

The en-bloc transplantation of more than three intra-abdominal organs is known as a Multi-visceral transplantation (MvTx). The liver, stomach, pancreas, duodenum, small intestine, and a portion of the colon are the most common organs transplanted as part of an MvTx [1].

This prolonged procedure is associated with significant blood loss, metabolic abnormalities, temperature fluctuation, fluid and electrolyte shifts, and coagulopathy [2]. A successful

MvTx requires strong multidisciplinary teamwork of transplant surgeons, anesthesiologists, and intensivists. Anesthesiologists play an essential role in the MvTx management team. They will encounter several challenging intraoperative situations [2]. However, the anesthetic considerations of MvTx are less apparent. In this case series, the anesthetic aspects of five MvTx cases at a single referral center were discussed.

CASE PRESENTATION

The authors report five cases of MvTx between May 2019 and January 2020 in the Abu-Ali Sina Hospital, Shiraz, Iran. A written consent form was obtained from patients. Even though assessment of cardiovascular and pulmonary status is the cornerstone of preoperative evaluations, consideration of hepatic

*Correspondence: Fatemeh Khalili, MD, Anesthesiology and Critical Care Research Center, Shiraz University of Medical Sciences, Shiraz, Iran

ORCID: 0000-0003-3926-6423

Tel: +98-71-36281460

E-mail: monakhalilimd@gmail.com

and renal function and coagulation status is imperative. After standard monitoring of the patients, rapid-sequence induction of anesthesia due to delayed gastric emptying was done with intravenous fentanyl (4 micro/kg), propofol (2 mg/kg), and high-dose rocuronium (1.2 mg/kg) or succinylcholine (1-2 mg/kg). Then, after intubation, midazolam 50 micro/kg, and morphine 0.1 mg/kg were maintained with propofol infusion (0.1-0.2 mg/kg/min) and oxygen/air mixture.

In these cases, the following information is addressed: Demographic data (age, BMI, and sex); comorbid disease; the cause of intestinal failure; and MVTx indications; outpatient department parenteral nutrition; time on the waiting list (WL); ABO compatibility; length of hospitalization before transplantation (days); length of TPN (days); and preoperative laboratory data such as hemoglobin, albumin, total and direct bilirubin, and serum creatinine (Table 1).

Table 2 includes data on intraoperative anesthesia, such as the number of bleedings, blood products transfusion, albumins and fluids administration, operation time, mean Cold Ischemia Time (CIT), and Warm Ischemia Time (WIT).

Postoperative complications like acute and chronic rejection rates, their causes, antibody-mediated rejection, infection (site/pathogens), CMV infection, and other complications that occurred during a 6-month follow-up were also recorded. Moreover, survival rates were also considered (Table 3).

CASE 1

She was a 44-year-old woman diagnosed with a well-differentiated neuroendocrine tumor (NET, grade 1, carcinoid tumor); she had undergone multiple operations, including colectomy and small bowel resection anastomosis at another center. She developed small bowel tumor recurrence, single liver metastasis, short bowel syndrome, and enterocutaneous fistula. The patient was referred to the center while complaining of food intolerance and

bowel obstruction symptoms as well as gastric outlet obstruction. She was admitted and received gastrointestinal rest and TPN for two months. She underwent classic MVTx and had a good postoperative period. She survived the event (Fig 1).

CASE 2

She was a 52-year-old woman known as a case of celiac and superior mesenteric arteries (SMA) aneurysm admitted to our center. She suffered from severe abdominal pain after the diagnosis. SMA and celiac artery aneurysm reconstructions were performed using a saphenous vein interposition graft, but graft thrombosis occurred post-operation. The patient underwent immediate classic MVTx. She survived for three months; afterward, she died of graft versus host disease (GVHD) and pneumonia in the hospital.

CASE 3

She was a 35-year-old woman who had undergone laparoscopic right hemicolectomy due to a colonic polyp and subsequent GI bleeding. She was discharged from the hospital; however, a few days later, she presented with abdominal pain, leukocytosis, and thrombocytosis in the laboratory data. Doppler ultrasonography showed portal vein thrombosis (PVT), and exploratory laparotomy revealed extensive bowel gangrene. Small bowel resection and anastomosis failed three times in the local hospital. She was admitted with short bowel syndrome, TPN-associated liver failure, and fistula. She received some TPN and then established a GI continuity by duodeno-colic anastomosis surgery. TPN continued, and MVTx was performed 79 days later. Klebsiella pneumonia and severe sepsis deteriorated her condition during her hospital stay; unfortunately, she died two months after MVTx.

CASE 4

She was a 39-year-old woman with a known case of diabetes mellitus, opium addiction,

Table 1: Demographic and Preoperative data.

Characteristics	Case 1	Case 2	Case 3	Case 4	Case 5
Age	44	51	35	39	47
Sex	F	F	F	F	M
BMI	19.6	20	17.5	14.5	19
Cause of intestinal failure	NET (carcinoid) with liver metastasis	Abdominal aneurysm	PVT after laparoscopic colectomy	Diffuse mesenteric & PVT	Klatskin tumor
ABO typing	A+	A+	A-	A+	O+
Comorbidity	—	—	IFLAD	DM Addiction	—
Waiting time (days)	62	2	101	197	30
Length of hospitalization before TX (days)	62	2	79	25	30
Outpatient department PN	yes	No	No	No	No
Length of TPN (days)	62	—	110	24	20
Hemoglobin (g/dL)	11.9	12.7	9.3	9.4	9.8
Albumin (mean)	2.3	2.6	2.9	3.9	3.5
Total bilirubin (mean)	0.58	2.59	3.9	1.8	2.5
Serum creatinine (mean)	0.7	0.8	0.9	0.7	0.8

non-cirrhotic portal hypertension, and protein C deficiency, developed with extensive Porto mesenteric thrombosis. She was admitted to the hospital with severe abdominal pain, food intolerance, lack of response to band ligation, and repeated upper gastrointestinal bleeding. She received TPN for 25 days and was then scheduled for classic MvTx. She had one episode of acute graft rejection on the 8th day post-operation, which was resolved with high-dose steroids; she was finally discharged from the hospital 25 days after MvTx, and she was well at the follow-up 6 months later.

CASE 5

A 47-year-old man who was suffering from a klatskin tumor with obstructive jaundice was admitted to the hospital. A PTBD was inserted, and a left hepatectomy was performed. He received an entire course of adjuvant chemotherapy and then returned with a recurrent tumor and GOO one year later. TPN started, and metastatic workup revealed no distant metastasis. Afterwards, cluster MvTx was performed, and he had an uneventful postopera-

tive period until he had a high-output fistula. His fistula drain had shrunk to <1100cc daily from TPN, octreotide, and GI rest. Finally, he developed pneumonia and severe sepsis and died two months later in the hospital.

Ethical Considerations

Written consent form was obtained from patients. This study approved by Ethics Committee of Shiraz University of Medical Sciences (IR.SUMS.MED.REC.1401.043).

DISCUSSION

Multi-visceral transplantation (MvTx) has gained acceptance as a therapeutic procedure for intestinal failure with life-threatening complications of parenteral nutrition (PN), rare cases of vascular abdominal catastrophes, and some cases of low-grade neoplastic tumors and desmoids involving the mesenteric root. This prolonged procedure is associated with significant blood loss, metabolic abnormalities, temperature fluctuations, fluid and

Table 2: Intraoperative data.

Parameters	Case 1	Case 2	Case 3	Case 4	Case 5
Ringer lactate (mL)	500	—	—	500	500
N/S (mL)	2500	2500	5500	2500	5500
Gelatin (mL)	1000	1000	—	2000	—
Fluid cc/kg/h	17	13	15.5	14.5	15.5
Albumin 5% (g)	20	30	40	30	30
Packed cell transfusion	5bag	3bag	5 bag	7bag	4bag
Cryoprecipitate/FFP/platelet transfusion	—	—	—	5 bag/ 5 bag/ 5bag	—
Approximate blood loss (mL)	1500	1500	3000	5000	2000
HCO ₃ , before reperfusion	13.6	15.5	12.5	22.6	15.9
K serum before reperfusion	3	3.4	2.6	3.4	3.5
BE, before reperfusion	-13	-11.7	-13.9	-1.7	-9.7
HCO ₃ , 30 min after reperfusion	21.6	20.3	14.2	19.2	21
BE, 30 min after reperfusion	-3.3	-5.1	-6.4	-6.5	-3.5
K serum, 30 min after reperfusion	3.9	3.2	2.7	2.7	2.7
Operation time (min)	300	300	420	360	420
CIT (min)	240	270	120	180	160
WIT (min)	60	30	35	60	45

electrolyte shifts, and coagulopathy. It should be noted that malnutrition, dehydration, reduced physiologic reserves due to long-standing intestinal failure, chronic TPN, and liver dysfunction make these challenges more difficult to overcome [3]. These pathophysiologic considerations corroborate the anesthetic plan for patients undergoing multi-visceral transplantation.

Patients' Monitoring

In addition to peripheral access, a large-bore introducer should be embedded in the right internal jugular vein for fluid resuscitation, blood product transfusion, and vasopressor infusion. Patients presenting for multi-visceral transplantation are critically ill, and long-term parenteral nutrition increases the risk of prior venous thrombosis. Therefore, bedside ultrasound is recommended to identify the target central vein [4]. A radial arterial catheterization, in addition to standard monitors (non-invasive blood pressure; electrocardiogram; pulse oximetry;

capnography; and temperature monitoring), is suggested for the beat-to-beat evaluation of mean arterial blood pressure, systolic pressure variations in estimating intravascular volume status, and the continuous evaluation of blood gases, hemoglobin, and electrolytes [5]. During the MVTx, wide temperature fluctuations secondary to prolonged exposure of the viscera are common; hence, the maintenance of normothermia is essential to prevent coagulopathy and cardiac instability, followed by hypothermia [4]. Accordingly, we measured core body temperature through the esophageal probe and considered a forced-air warming blanket and fluid warmer. Continuous blood glucose (BS) monitoring and its correction are necessary in all cases that have recently undergone TPN to prevent hypoglycemia following the abrupt discontinuation of TPN.

Intraoperative Concerns

Fluid resuscitation is crucial because of the prolonged operation time, significant blood loss, and excessive third-space losses. Therefore, conservative fluid management

Table 3: Complications during 6 month follow-up.

Parameters	Case 1	Case 2	Case 3	Case 4	Case 5
Infection (site/pathogenesis)	Esophagitis (HSV)	Sputum (kelebsiella)	BSI & pneumonia (kelebsiella)	BSI (VRE)	Pneumonia (kelebsiella)
CMV infection	—	—	—	—	—
Other complication	Entrocotaneous fistula	Pancreatitis & small bowel obstruction	—	Pancreatitis & small bowel obstruction	Entrocotaneous fistula
Patient status	Alive	Expired	Expired	Alive	Expired
Cause of death	—	GVHD	Sever sepsis	—	Sever sepsis
Survival length (months)	—	3 month	2 month	—	2 month

and the application of a pulse counter cardiac output (PICCO) system are the recommended fluid management strategies to restore intravascular volume [6]. In this study, PICCO was used to evaluate pulse pressure variation (PPV) and stroke volume variation (SVV) which predict the preload volume and fluid responsiveness.

Colloid solutions are more effective plasma volume expanders than crystalloids and reduce the severity of bowel edema. Studies suggest that the optimal crystalloid-to-colloid volume ratio is approximately 60:40. A balanced fluid strategy is a well-directed technique to maintain mean arterial pressure (MAP) > 60 mm Hg and target CVP > 10-12 mm Hg. It aims to stabilize hemodynamic status and improve organ perfusion [7]. To prevent bowel edema, we considered a conservative fluid strategy that maintains the target CVP < 10 mm Hg with the concomitant administration of vasopressor infusions (norepinephrine, vasopressin, and/or epinephrine) if the MAP was < 60 mmHg. It should be noted that the mean \pm SD of total volume administration was 15 ± 1 cc/kg/h which was given as normal saline solution 0.9%/albumin 20% (60%/40%).

Some researchers have suggested that rotational thromboelastometry (ROTEM) can be applied for the evaluation of coagulation status in MvTx [8]. Using intra-operative ROTEM analysis in our center revealed that the majority of patients were in a 'hypercoagulable status' and no blood

products were required with the exception of the fourth patient, who received fresh frozen plasma (FFP), cryoprecipitate, and platelet to correct microvascular bleeding caused by a massive transfusion.

Bleeding would be either surgical or coagulopathic or both during the MvTx. It might be more severe in patients with adhesions from previous abdominal surgeries, portal hypertension, or portal vein thrombosis (PVT) [9]. The average intraoperative blood loss was 2600 cc. To achieve adequate tissue oxygenation, the hemoglobin level should be maintained at a level of 7-10 g/dL. On the other hand, overcorrection of hemoglobin should be avoided due to an enhanced risk of vascular graft thrombosis [10]. In our series, the average Hemoglobin level was 10.62 g/dl and the average transfused packed red blood cell was 4 ± 1 bag.

About 47% of patients undergoing small bowel transplants experience post-reperfusion syndrome (PRS) [11]. PRS is a life-threatening hemodynamic compromise related to the number of reperfused organs. It is characterized by marked decreases in MAP and systemic vascular resistance, as well as moderate increases in pulmonary arterial pressure and central venous pressure. This syndrome may also develop cardiovascular and metabolic abnormalities when the MAP is less than 60 mm Hg or 30% below the pre-unclamping baseline value, lasting for at least 1 min, within 10 min after unclamping [12].

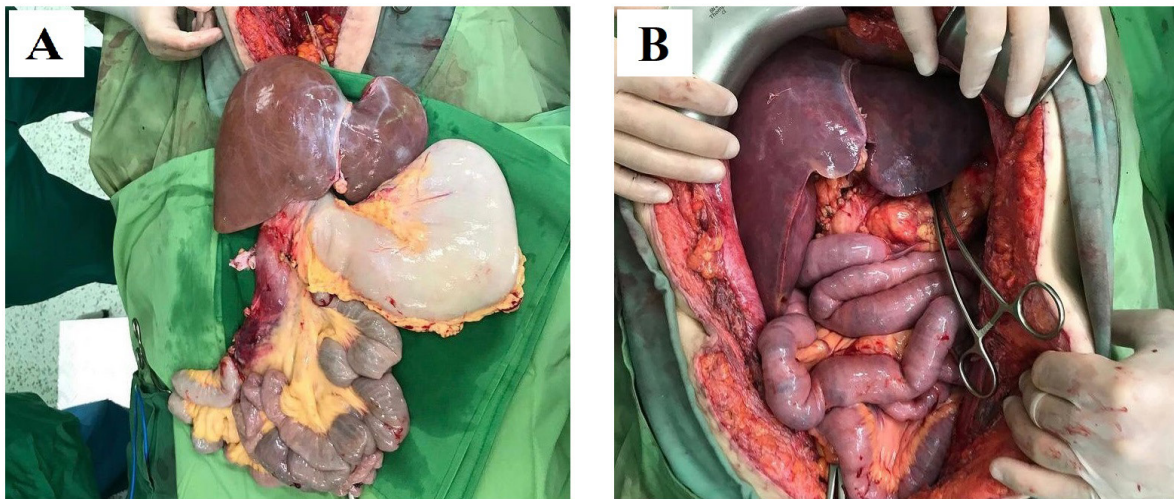


Figure 1: A) Recovered organs before implantation, B) Implanted organs before reperfusion.

Despite the synergistic effects of the similar number of grafts, PRS occurred in all these five cases, but severe PRS, which needed continuous vasopressin and norepinephrine infusion, happened in only NET. It is well-documented that several factors contribute to PRS development (i.e., hyperkalemia, acidosis, sudden hypothermia, vasoactive substances like free radicals, endotoxins, inflammatory cytokines, and acidotic compounds produced by the graft or intestine) [12]. Each of these factors must be considered and treated prior to the un-clumping phase. Indeed, TPN supplements contain potassium; on the other hand, concomitant liver graft reperfusion may enhance the intensity of hyperkalemia. Thus, serial measurements of plasma potassium have suggested keeping the potassium level below 4 mmol/L before the un-clumping phase and revascularization [13]. Treatment options for hyperkalemia include simultaneous administration of insulin and hypertonic-glucose, calcium gluconate 10%, sodium bicarbonate, and diuretics [14]. Aortic cross clamp and PRS may also contribute to renal injury. Studies suggested that the risk of post-transplant renal failure was 50% in MvTx, but we did not observe any cases of CRRT or dialysis-requiring acute kidney injury [15]. It might be related to maintaining MAP > 60 mmHg and improving kidney perfusion pressure with an infusion minimum dose of vasopressor during the clumping and

unclamping phase [15].

Despite the fact that numerous protocols are in use at different centers, the intraoperative mainstay of our center's protocol is made up of two immunosuppressive drugs: anti-thymocyte globulin (thymoglobulin) 1 mg/kg and methylprednisolone 1mg/kg are infused simultaneously at the start of the procedure and maintained postoperatively.

According to a previous study, the most frequent postoperative complications are acute allograft rejection and infection [4]. Although a wide range of antibiotics and antifungals are a part of our center's protocol, sepsis is the most important cause of mortality. It might be related to MvTx procedures being associated with a significant risk of immunomodulation and immunosuppression.

Considering the limited and retrospective nature of the data herein discussed, there may be some concerns regarding the potential bias or overestimation of management. However, this is the first study in the largest transplant center in the Middle East to present a series of patients undergoing MvTx, and future studies are still recommended to assay other aspects of this technique, especially postoperative care and patient outcomes.

In conclusion, each phase of the MvTx has its own unique cautions. Careful preoperative planning (patient selection, nutritional status, and optimization of the patient's condition), vigilant intraoperative anesthetic consideration (hemodynamic and fluid management), and postoperative infection prevention are imperative to achieve the best outcomes.

ACKNOWLEDGMENTS

The authors would like to deeply thank all the staff working in operation theaters of Abu-Ali Sina hospital for their kind help to conduct this study.

CONFLICTS OF INTEREST: None declared.

FINANCIAL SUPPORT: None.

REFERENCES

1. Kato T, Tzakis AG, Selvaggi G, et al. Intestinal and multivisceral transplantation in children. *Ann surg* 2006;**243**:756.
2. Gologorsky E, Fukazawa K. Anesthesia for Multivisceral Transplantation. *Anesthesia and Perioperative Care for Organ Transplantation: Springer*; 2017. p. 517-24.
3. Cruz RJ, Jr, Garrido AG, Silva MR. Early hemodynamics and metabolic changes after total abdominal evisceration for experimental multivisceral transplantation. *Acta Cirurgica Brasileira* 2009;**24**:156-61.
4. Jacque JJ. Anesthetic considerations for multivisceral transplantation. *Anesthesiol Clin North Am* 2004;**22**:741-51.
5. Faenza S, Arpesella G, Bernardi E, et al., editors. Combined liver transplants: main characteristics from the standpoint of anesthesia and support in intensive care. *Transplantation proceedings*; 2006: Elsevier.
6. Hung M-H, Chan K-C, Chang C-Y, Jeng C-S, Cheng Y-J. Application of Pulse Contour Cardiac Output (PiCCO) System for Adequate Fluid Management in a Patient with Severe Reexpansion Pulmonary Edema. *Acta Anaesthesiologica Taiwanica* 2008;**46**:187-90.
7. Lomax S, Klucniks A, Griffiths J. Anaesthesia for intestinal transplantation. *Continuing Educ Anaesth Crit Care Pain* 2011;**11**:1-4.
8. Planinsic RM. Anesthetic management for small bowel transplantation. *Anesth Clin* 2004;**22**:675-85.
9. Sudan D. The current state of intestine transplantation: indications, techniques, outcomes and challenges. *Am J Transplant* 2014;**14**:1976-84.
10. Zerillo J, Kim S, Hill B, et al. Anesthetic management for intestinal transplantation: A decade of experience. *Clin Transplant* 2017;**31**:10.1111/ctr.13085.
11. Planinsic R, Nicolau-Raducu R, Aggarwal S, Hilmi I, Abu-Elmagd K. Post reperfusion changes during small bowel transplantation. *Transplantation* 2004;**78**:410-1.
12. Siniscalchi A, Cucchetti A, Miklosova Z, et al. Post-reperfusion syndrome during isolated intestinal transplantation: outcome and predictors. *Clin Transplant* 2012;**26**:454-60.
13. Nguyen-Buckley C, Wong M. Anesthesia for Intestinal Transplantation. *Anesth Clin* 2017;**35**:509-21.
14. Aggarwal S, Abu-Elmagd K, Amesur N, Thaete F, Planinsic R, Zak M. Patency of the central vein system in patients undergoing SBTx: ultrasonography versus contrast venography. *Anesth Analg* 2002;**94**:579.
15. Williams K, Lewis JF, Davis G, Geiser EA. Dobutamine stress echocardiography in patients undergoing liver transplantation evaluation. *Transplantation* 2000;**69**:2354-6.